Clinical Sports Medicine Update

Core Muscle Injury

Evaluation and Treatment in the Athlete

Julianne M. Forlizzi,* MD, Mark B. Ward,* BS, James Whalen,† ATC, Thomas H. Wuerz,* MD, and Thomas J. Gill IV,*‡§ MD
Investigation performed at New England Baptist Hospital, Boston, Massachusetts, USA

Background: Pain in the groin region, where the abdominal musculature attaches to the pubis, is referred to as a ''sports hernia,'' ''athletic pubalgia,'' or ''core muscle injury'' and has become a topic of increased interest due to its challenging diagnosis. Identifying the cause of chronic groin pain is complicated because significant symptom overlap exists between disorders of the proximal thigh musculature, intra-articular hip pathology, and disorders of the abdominal musculature.

Purpose: To present a comprehensive review of the pathoanatomic features, history and physical examination, and imaging modalities used to make the diagnosis of core muscle injury.

Study Design: Narrative and literature review; Level of evidence, 4.

Methods: A comprehensive literature search was performed. Studies involving the diagnosis, treatment, and rehabilitation of athletes with core muscle injury were identified. In addition, the senior author's extensive experience with the care of professional, collegiate, and elite athletes was analyzed and compared with established treatment algorithms.

Results: The differential diagnosis of groin pain in the athlete should include core muscle injury with or without adductor longus tendinopathy. Current scientific evidence is lacking in this field; however, consensus regarding terms and treatment algorithms was facilitated with the publication of the Doha agreement in 2015. Pain localized proximal to the inguinal ligament, especially in conjunction with tenderness at the rectus abdominis insertion, is highly suggestive of core muscle injury. Concomitant adductor longus tendinopathy is not uncommon in these athletes and should be investigated. The diagnosis of core muscle injury is a clinical one, although dynamic ultrasonography is becoming increasingly used as a diagnostic modality. Magnetic resonance imaging is not always diagnostic and may underestimate the true extent of a core muscle injury. Functional rehabilitation programs can often return athletes to the same level of play. If an athlete has been diagnosed with athletic pubalgia and has persistent symptoms despite 12 weeks of nonoperative treatment, a surgical repair using mesh and a relaxing myotomy of the conjoined tendon should be considered. The most common intraoperative finding is a deficient posterior wall of the inguinal canal with injury to the distal rectus abdominis. Return to play after surgery for an isolated sports hernia is typically allowed at 4 weeks; however, if an adductor release is performed as well, return to play occurs at 12 weeks.

Conclusion: Core muscle injury is a diagnosis that requires a high level of clinical suspicion and should be considered in any athlete with pain in the inguinal region. Concurrent adductor pathology is not uncommon.

Keywords: hip; pelvis; groin pain; ice hockey; rugby; ultrasonography; muscle injuries

Groin pain frequently occurs in athletes at all levels of competition. Acute groin pain is usually self-limiting and typically will respond to nonoperative measures; however, persistent symptoms may limit athletic performance. Identifying the cause of chronic groin pain is clinically challenging because significant symptom overlap exists between disorders of the proximal thigh, intra-articular hip pathology, and disorders of the abdominal musculature.[33] Acute groin injuries are often strains or low-grade tears of the hip flexors and/or adductor tendons, which are treated expectantly.[48] Chronic, refractory pain in the groin at the level of the transversalis fascia with weakening of the posterior wall of the inguinal canal and involvement of the rectus abdominis is referred to as a "sports hernia" or "athletic pubalgia" or, more recently, "core muscle injury." Core muscle injury is most common in athletes who repeatedly engage their core and proximal thigh musculature during competition, and its effect ranges from mild impairment to inability to participate.[17] Athletes who undergo repetitive hyperextension, kicking, sprinting, or cutting in sports such as soccer, football, hockey, and rugby are especially prone to this condition.[25] In soccer players, athletic pubalgia is estimated to account for 10% to 13% of all injuries per year.[33] One study reported that core muscle injury was the diagnosis in almost half of 189 athletes who experienced chronic groin pain,[20] whereas another

The American Journal of Sports Medicine
1–9
DOI: 10.1177/03635465211063890

study identified core muscle injury as the underlying pathology in 39% of patients.[27]

Core muscle injury has become a topic of interest due to the frequency of reported symptoms as well as increased recognition of this problem. This condition may coexist with adductor tendinopathy and/or a true inguinal hernia. Currently, there is no universal, evidence-based consensus on definition or management for this entity.[10] The Doha agreement was published in 2015 to help standardize terms and definitions regarding diagnosis and treatment of hip conditions including core muscle injury.[51] This review aims to elucidate the pathoanatomic knowledge, diagnostic tools, and therapeutic options available to guide effective multidisciplinary approaches to an athlete with a core muscle injury.

PATHOANATOMY

A brief review of the abdominal wall layers is warranted, given the anatomic complexity. Tissue layers from superficial to deep include skin, external oblique muscle/fascia, internal oblique muscle/fascia, transversus abdominis muscle/fascia, transversalis fascia, and peritoneum. The rectus abdominis is a midline structure and inserts on the pubic tubercle (Figure 1). Notably, the most inferior fibers of the internal oblique aponeurosis and transversus abdominis combine to form the conjoined tendon and insert anterior to the rectus, resulting in a single fascial layer deep to the rectus abdominis in the lower 25% of the abdomen.[48] This region is potentially vulnerable, especially in the setting of relatively unconditioned core musculature compared with the proximal thigh/adductor musculature in a competitive athlete. Insult to the posterior wall of the inguinal canal results in loss of integrity at the canal and has been described as an early spectrum of injury in the development of direct hernias.[11]

The diagnosis of "sports hernia" was first described by Gilmore[20] based on experience with a series of soccer players treated for groin pain. The author defined the pathology as a torn external oblique aponeurosis causing dilation of the superficial inguinal ring, a torn conjoined tendon, and subsequent dehiscence between the inguinal ligament and conjoined tendon. His discovery earned the moniker "Gilmore's groin."[33] This concept was further investigated in athletes who underwent surgical treatment and was the first mention of the term *pubalgia*. The authors described sports hernias as "non-palpable, small direct or indirect hernias or microscopic tears or avulsions of the internal oblique muscle in the area commonly referred to as the conjoined tendon."[49] This description varies across the literature

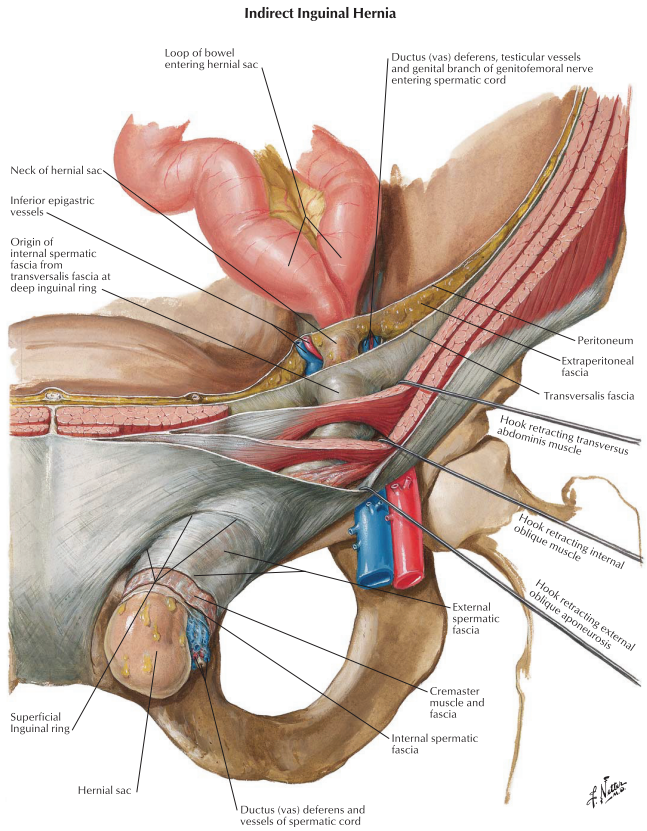

Figure 1. Anatomy of the layers of the abdominal wall demonstrating an indirect hernia. Rectus abdominis muscle unlabeled, at midline. (2022. Used with permission of Elsevier. All rights reserved.)

from microscopic tearing to macroscopic avulsions of the conjoined tendon, with the common trait being a weak posterior wall at the level of the transversalis fascia.[14] Later descriptions theorized the pubic symphysis as a pivot point. The rami are typically balanced between a superiorly directed pull by the rectus abdominis and internal oblique and an inferiorly directed pull by the adductors. The pull of the relatively stronger adductors overwhelms the abdominals with resultant shearing forces at the hemipelvis, causing attenuation and eventual tearing beginning at the transversalis fascia and extending into the overlying abdominal musculature.[34]

The cause of pain can be elusive, but one hypothesis is that discomfort is caused by entrapment of the ilioinguinal and/or genitofemoral nerves. Specifically, the genital

§Address correspondence to Thomas J. Gill IV, MD, New England Baptist Hospital, 125 Parker Hill Avenue, Boston, MA 02120, USA (email: tgill@partners.org).
*New England Baptist Hospital, Boston, Massachusetts, USA.
†New England Patriots, Foxboro, Massachusetts, USA.
‡St Elizabeth's Medical Center, Brighton, Massachusetts, USA.
Submitted May 14, 2021; accepted August 30, 2021.
One or more of the authors has declared the following potential conflict of interest or source of funding: J.M.F. has received support for education from Arthrex, Smith & Nephew, and Kairos Surgical. T.H.W. has received consulting fees from ConMed Linvatec. T.J.G. has received consulting fees from DePuy Synthes and holds stock in VisionScope Technologies. AOSSM checks author disclosures against the Open Payments Database (OPD). AOSSM has not conducted an independent investigation on the OPD and disclaims any liability or responsibility relating thereto.

branch of the genitofemoral nerve may be inflamed or surrounded by scar tissue.[11] Cadaveric studies demonstrate multiple anatomic variants of the genitofemoral branches. These branches often merge with the ilioinguinal nerve entering the inguinal canal, or they may pierce the border between the inguinal ligament and external oblique musculature.[4] One study identified 4 distinct types of cutaneous branching patterns for the ilioinguinal and genitofemoral nerves.[42] One retrospective analysis of operative patients included special attention to these nerves and found them to be "normal" in all 35 athletes at the time of surgery.[29]

In the senior author's (T.J.G.) experience, a sports hernia occurs due to the overuse of disproportionately developed musculature in the pelvic girdle. In particular, there is dramatic overdevelopment of the aponeurosis of the internal oblique and transverse abdominis, leading to compression of the floor of the inguinal canal. This phenomenon leads to disproportionate tension across the lateral pubis with canal bowing. Pain develops across the pubis with compression of the genital branches of the genitofemoral nerve. The muscular pull overwhelms the strength of the fascial and tendinous attachments, causing microtearing with eventual progression to symptomatic tears. In addition, as the posterior wall weakens and widens, the rectus abdominus muscle retracts superomedially, causing increased tension at its insertion and pain at the symphysis pubis.[38] Special attention to this area of the conjoint tendon is required if surgical intervention is planned.

HISTORY AND PHYSICAL EXAMINATION

Groin pain is commonly reported at both professional and recreational levels, especially in soccer, football, and hockey athletes. The majority of patients with true core muscle injury will report an insidious onset of deep groin pain aggravated by activity.[26] Occasionally, a single traumatic episode is present. In 1 study, >70% of athletes were able to recall a specific incident.[34] Symptoms begin unilaterally but often radiate to the inner thigh, to the perineum/scrotum, or across the midline as patients alter the biomechanical forces across their pelvis to accommodate the original injury.[26,35] The hallmark of core muscle injury is that patients are asymptomatic at rest. The onset of groin pain recurs immediately on resumption of activity. Pain begins in the groin but may present in the adductors, perineum, rectus musculature, inguinal ligament, and/or scrotal areas.[17,26,33] In the early stages, symptoms occur after activity as a generalized ache (ie, after practice). As the pathology progresses, the athlete will typically report the onset of symptoms while competing, with symptoms eventually becoming so frequent that the athlete is unable to stride, turn, or kick without a sharp, stabbing pain.[21,25] Activities causing an increase in intra-abdominal pressure such as sneezing, coughing, sprinting, and sit-ups also aggravate symptoms.[17,21,35]

Given the difficult nature of the diagnosis of core muscle injury, other causes must be investigated during a physical examination. The examination begins with the patient in the supine position, and the hip is evaluated first. Flexion, adduction, and internal rotation (FADIR) and flexion, abduction and external rotation (FABER) testing are performed to evaluate the hip and sacroiliac joints. The sensitivity and specificity of the FADIR test for intra-articular pathology such as labral tear have been reported to be as high as 99% to 100% in patients with at least 3 months of clinical symptoms.[43] FABER testing is used for sacroiliac symptoms, with a sensitivity and specificity of 65% to 75% but a high positive predictive value of 90%.[40] Differentiating core muscle injury from intra-articular hip conditions is of utmost importance, and patients may have coexisting pathology. Should surgical intervention be warranted, addressing both femoroacetabular impingement (FAI) and core muscle injury concomitantly demonstrates improved outcomes and a high rate of return to sports.[14,30,31]

The pelvic attachment of the adductor longus should be palpated because adductor longus pathology is frequently seen in conjunction with a core muscle injury. Resisted adduction performed with the patient in a supine position is a specific examination maneuver for adductor tendon pathology.[43] Additionally, pain may be experienced with adductor stretch. However, patients frequently report that this pain is secondary and less severe than that which is experienced along the inguinal canal during the valsalva maneuver or resisted sit-up.[21] The pubic symphysis and rectus abdominis should be palpated to evaluate for osteitis pubis. Other causes of groin pain may include anterior inferior iliac spine avulsion or hip pointers, which should be discernable based on the area of tenderness. Finally, a resisted sit-up is performed, and if the patient experiences pain at the proximal pubis, this is highly suggestive of a core muscle injury, particularly the rectus abdominis. The clinician should perform a detailed lumbar spine examination if any symptoms are thought to arise from referred pain from a lumbar disk.

Next, the patient is placed in the standing position, and the external ring and inguinal canal are palpated. An inguinal hernia must always be ruled out, as prompt referral to a general surgeon is in the patient's best interest. The diagnosis of core muscle injury is suspected when the patient describes the pain as occurring proximal to the inguinal ligament.

The differential diagnosis of groin pain in the athlete should include urogynecological pathology specific to the athlete's biological sex because these conditions necessitate referral to the appropriate specialist.[14] Male patients with groin pain presenting with scrotal discomfort may in fact have hydrocele/varicocele or testicular neoplasm, whereas female patients with genital discomfort may have endometriosis, pelvic inflammatory disease, or pelvic floor dysfunction.[14,48] Patient reports of bowel or bladder changes, pelvic muscle spasm or cramping, or dyspareunia are indications for referral to a gynecologist or urologist for further workup.

In summary, a focused clinical examination should be performed with care so as not to miss femoral neck stress fractures, slipped capital femoral epiphyses (in an adolescent population), avascular necrosis of the femoral head, or neoplastic conditions of the genital or lower gastrointestinal systems. With regard to physical examination maneuvers, the

scour test, pain with maximum internal hip rotation, and the hop test provide useful information.

DIAGNOSTIC IMAGING

Imaging is not required to make a diagnosis of athletic pubalgia, but it can be helpful. The first step in imaging is acquiring plain standing radiographs of the hip and pelvis. These radiographs can identify intra-articular hip pathology, including osteoarthritis, hip dysplasia, FAI, or extra-articular pathology including stress fractures, avulsion fractures, neoplasms, and/or osteitis pubis. The lack of intra-articular findings is common in patients with a core muscle injury.[53]

Dynamic ultrasonography is increasingly used as a diagnostic tool for athletic pubalgia. Advantages include its noninvasive nature and lack of radiation exposure. Ultrasonography is also inexpensive. The major disadvantage of ultrasonography is that it is highly operator-dependent with variable reproducibility.[11,14,48] Ultrasonographic evaluation of athletic pubalgia has been described in the radiology literature and should be performed with the patient relaxed as well as in a strained setting (ie, valsalva) to evaluate the posterior inguinal wall for deficiency.[11] This technique also evaluates for direct or indirect inguinal hernias as well as femoral or obturator hernias, which are other potential sources of groin pain.[50] In the setting of radiographic FAI, ultrasonography has been used to demonstrate the high incidence of concomitant pathology. In an evaluation of 83 hips, 41% of patients had evidence of groin herniation, and 23% had adductor tendinopathy.[39] Given the prevalence of overlapping pathology, the contralateral side should be evaluated for comparison, even if it is asymptomatic.

Magnetic resonance imaging (MRI) aids in diagnosis and can discern osseous anomalies such as stress reactions from soft tissue pathologies such as adductor tendinitis (Figure 2). Axial and coronal oblique sequences through the pubic symphysis should complement the standard MRI sequences.[36] Additionally, high-resolution MRI may help identify subtle tearing of the rectus abdominis or conjoint tendon fibers seen in athletic pubalgia.[11] A complete disruption at the aponeurosis of the adductor or the rectus abdominis is pathognomonic for a sports hernia. If intra-articular pathology is suspected, a magnetic resonance arthrogram is particularly useful, although 3.0-T MRI with a focus on the fast-spin sagittal and coronal sequences may obviate the need for a more invasive arthrography. One advantage of magnetic resonance arthrography is the ability to perform a diagnostic and potentially therapeutic corticosteroid injection at the time of imaging.[48] MRI evaluation of 32 patients with surgery-confirmed core muscle injury demonstrated that the most common findings on imaging were increased T2-weighted signal in 1 or both pubic bones, attenuation of abdominal wall myofascial layers, bulging of the abdominal wall, and increased T2-weighted signal within 1 or more groin muscles (adductors/pectineus).[5] Although sensitive for the diagnosis of athletic pubalgia, these findings are not specific, as many patients with sports hernia lack pathological findings on MRI.[14]

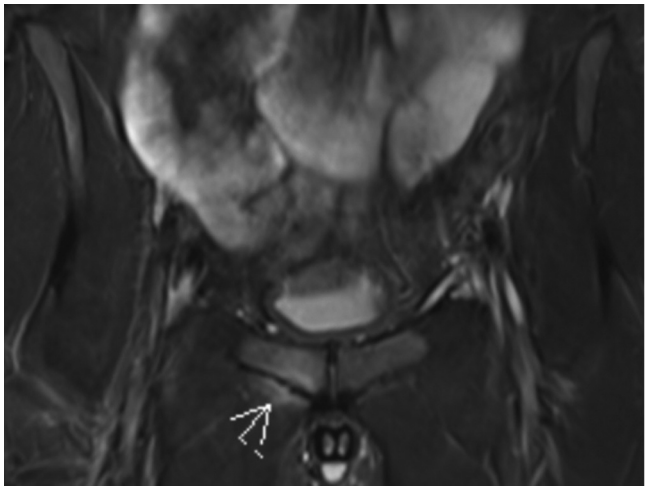

Figure 2. Coronal short tau inversion recovery magnetic resonance imaging sequence demonstrating edema at the adductor longus insertion in a patient with adductor tendinopathy (white arrow).

NONOPERATIVE TREATMENT

Before any surgical intervention, nonoperative management should be attempted with rest and activity modification. Stretching and modalities such as soft tissue manipulation can be helpful. As with other hip pathology, physical therapy should encompass the entire kinetic chain of the lumbopelvic region to address any potential imbalances. A focus on core strengthening, postural balancing, and improving the dynamic relationship of regional musculature is of utmost importance.[35] Adductor strengthening and stretching are key components of rehabilitation due to the possibility of concurrent symptoms. After a 3-month period of rehabilitation, including low-resistance and high-repetition activity, a gradual progression to sports should be undertaken with care taken to avoid inciting activities until the patient is appropriately rehabilitated.

Diagnostic injections of anesthetic, corticosteroid, or both may be attempted in the office setting. These injections should be placed at the site of maximal tenderness. Fluoroscopically guided pubic symphyseal injections have been shown to have a benefit in their diagnostic and therapeutic efficacy for osteitis pubis.[48] Low-volume (ie, <5 mL) ultrasound-guided intra-articular anesthetic injections have also been advocated to distinguish hip pathology from athletic pubalgia.[14] After injection, a repeat physical examination or exercise stress test may demonstrate resolution of pain, indicating hip pathology, or if the pain persists, athletic pubalgia may be more likely. One study evaluating patients with radiographic FAI noted that patients with a negative diagnostic hip injection were more likely to have concomitant groin herniation than those patients with a positive injection result. The authors advocated for the use of office-based injections to aid in diagnosis.[39] In the setting of midseason debilitating groin

pain in a high-level athlete, a corticosteroid injection may be considered to facilitate return to play.[14]

REHABILITATION PROGRAM

Nonoperative treatment is the initial treatment for core muscle injury and is successful in many cases. Initially, a brief period of rest and nonsteroidal anti-inflammatory medication is attempted, followed by a more formal physical therapy regimen.[15] Previous reports cite a minimum of 2 months of nonoperative therapy with rehabilitation emphasizing strength and stability including postural exercises.[22,54] As the rehabilitation program progresses, sport-specific activity should be incorporated to facilitate a return to play for the injured athlete.

Nonoperative modalities have been successful in athletes who participate in a variety of sports including soccer, ice hockey, and golf.[7,15,52] A 4-week core muscle injury exercise program with goals of first increasing flexibility, then increasing trunk and lower extremity strength, progressing to core stability, and finally increasing sport-specific function has been demonstrated to be effective at the professional golf level. Specifically, 13 sessions over a 4-week period allowed 1 athlete to resume full, pain-free participation with complete resolution of symptoms.[7] A similar program has demonstrated success at the level of professional hockey with 3 phases: phase I for pain management and flexibility, phase II for strength and core stabilization with attention to intrinsic core muscular deficits, and phase III for functional progression and sport-specific return to play. The player outlined had a traumatic injury diagnosed as sports hernia, and after a 49-day rehabilitation program he returned to the same level of play without pain or dysfunction; he continued to play professionally for 7 years.[52] The most important part of a nonoperative rehabilitation program is identification of muscular compensation/imbalances with requisite strength training and neuromuscular reeducation. Providers may choose to couple therapy with steroid injections to the pubic symphysis or adductor tendons as necessary.[15]

A final consideration in the athlete with core muscle injury is a functional, active rehabilitation program involving "repetitive, effortful muscle contractions . . . and progressive resistance exercises."[1] In a single-blinded, randomized controlled trial, this type of rehabilitation exhibited greater success when compared with conventional therapy. Pain scores were significantly lower, as was the rate of pain-free return to play (13/20 vs 3/20, respectively).[1] Treatment for core muscle injury should include this type of therapy to facilitate successful return to sport.

OPERATIVE TREATMENT

Operative management is considered after a 12-week trial of nonoperative rehabilitation, depending on the athlete. The surgical technique was initially described by Gilmore and included a plication of the transversalis fascia to bring together the conjoint tendon and the inguinal ligament and reapproximation of the external oblique aponeurosis.[20] Subsequently, a variety of open surgical techniques were developed and reported, including open repairs of the external inguinal ring with approximation of the conjoined tendon to the inguinal ligament,[21] repair of tears of the external oblique aponeurosis with mesh,[29] repair of the internal oblique aponeurosis augmented with mesh,[2] and imbrication of the transversalis fascia with attachment to the inguinal ligament.[47] Other techniques include open pelvic floor repair with repair of the anterior inferolateral edge of the rectus abdominis to the pubis and anterior ligaments.[34,35] The multitude of different techniques have demonstrated acceptable results, with smaller series showing 100% return to play.[12] Minimally invasive techniques have also been advocated. These include decompression of the genital branch of the genitofemoral nerve and a tension-free suture-only repair of the posterior inguinal wall.[37,38] Addressing concomitant adductor muscle tendinopathy benefits the patient. If this imbalance cannot be corrected nonoperatively during the trial of activity modification and physical therapy, then adductor tenotomy or repair is added to the procedure.[2,3,31,35]

The senior author's recommendation to proceed with operative management of core muscle injury entails a relaxing myotomy of the aponeurosis of the internal oblique and transverse abdominis as it arches toward the pubis (Figure 3). The patient is brought to the operating room, placed on an operative table in the supine position, and placed under general anesthesia; then the abdomen is prepared and draped in sterile fashion. Surgical

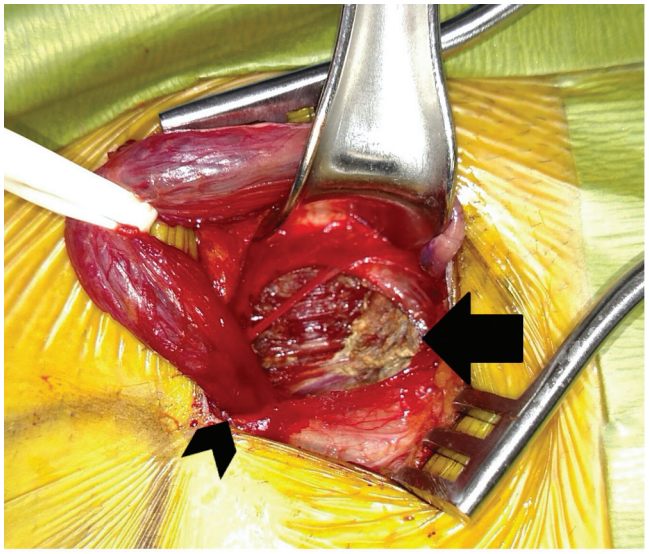

Figure 3. Relaxing myotomy of the conjoint tendon. The pubic symphysis site on the skin is circled with a surgical marker. The black arrow indicates the relaxed nature of the conjoint tendon insertion onto the symphysis after myotomy. A Penrose tube is seen retracting the spermatic cord outside the working window, which is diving deep into the inguinal ring (arrowhead).

preparation should include the groin region if an adductor tenotomy is also planned. A 4-cm oblique incision is made lateral to the pubic symphysis, and sharp dissection is used to reach the fascia overlying the external oblique. Hemostasis is paramount and is achieved with an electrocautery device. The fascia of the external oblique may contain a tear at baseline, and this tear is extended sharply to expose the floor of the inguinal canal. The spermatic cord is isolated and retracted gently with a Penrose tube (Figure 3). The relaxing myotomy of the conjoint tendon is completed while protecting the spermatic cord, and the preperitoneal mesh is sutured to cover the defect. Closure is completed with 3-0 Vicryl in the external oblique and Scarpa fascia. Skin is closed with absorbable suture.

The purpose of the myotomy is to release tension across the pubis, which has been drawn between the relatively strong adductors and relatively weak core musculature. To reinforce the weak floor of the canal, a mesh augment is used, and this mesh overlies the myotomy to prevent the development of a direct inguinal hernia. If an adductor tenotomy is performed, an additional incision is placed 1 cm distal to the inguinal crease, deep fascia is incised, and the adductor longus tendon is identified. A right-angled clamp is used to isolate this tendon with care to avoid the anterior branch of the obturator nerve. Electrocautery is used to perform a tenotomy with visual confirmation of tendon displacement distally. The wound is carefully closed in layers; absorbable skin suture and Dermabond (Ethicon) are recommended in the skin layer.

Although many studies have addressed the epidemiological patterns, risk factors, diagnostic imaging, and outcomes regarding core muscle injury, few efforts have been made to standardize communication among practitioners. The Doha agreement, which was created in 2015 to accomplish these tasks, classified groin pain into 3 major categories: (1) adductor, iliopsoas, or inguinal and pubic-related groin pain; (2) hip-related groin pain; and (3) other causes of groin pain.[51] This consensus statement evaluated outcomes of both operative and nonoperative treatment of groin pain in athletes. Important factors to note from this updated review include commonly noted imaging findings in the setting of groin pain such as degenerative changes in the symphyseal joint, pubic bone marrow edema, and adductor insertional pathology, all of which can be seen on MRI scans. Furthermore, the group's analysis of the studies regarding treatment found moderate evidence to support laparoscopic hernia repair for inguinal-related groin pain because it "results in lower pain and higher percentage returning to play than conservative treatment."[51] Regarding adductor-related groin pain, moderate evidence supports active, supervised, multimodal treatment therapies as opposed to passive therapy modalities to encourage return to play. Also, "partial release of the adductor longus is effective for return to sport over time."[51] In essence, standardization of reporting quality and consistent use of patient-reported outcome measures as well as definitions among providers will help advance both clinical practice and research in the area.

POSTOPERATIVE REHABILITATION

For an isolated repair of core muscle injury, postoperative rehabilitation is straightforward. Once the incision has healed, at approximately 2 weeks, a return to running is allowed. Return to contact sports usually is permitted by 4 weeks. If an adductor tenotomy is performed in conjunction with the sports hernia repair, the rehabilitation course is prolonged. The rehabilitation program is divided into 3 phases. Phase I is the immediate postoperative phase. The goals of this phase are to enable wound healing and to prevent reattachment of the adductor longus tendon. The athlete's leg is kept abducted as much as possible for the first 3 days. Repeated abduction stretching is performed during this phase, with relative rest from exercise. An abduction brace may be considered but is not a part of the senior author's treatment algorithm. An abduction pillow can be useful in the immediate postoperative setting to help keep the hips abducted and prevent early scarring of the adductor longus tendons. This can be used in conjunction with daily abduction stretching. Phase II entails postoperative weeks 2 through 5. The goals of this phase are to continue adductor muscles stretching, prevent excess scarring, and improve flexibility with gradual return to athletic activity. Stretching exercises consist of progressively abducting the legs while standing, which is a progression from seated stretches in phase I. Walking for short distances is encouraged, as well as limited (10-15 minutes) segments on a stationary exercise bike. Strength is increased with the use of standing single-leg abduction exercises, supine single-leg leg lifts, standing single-leg circumduction maneuvers, and straight leg sit-ups. Phase III begins 6 weeks postoperatively. This phase entails a gradual return to running and sport-specific training. Each progressive phase is dependent upon completion of the preceding phase. Return to sport is allowed only when wound healing is complete; the athlete has a full, painless range of motion; adductor muscle activity is painless; and preoperative groin pain has resolved.

OUTCOMES OF OPERATIVE TREATMENT

Isolated Athletic Pubalgia

The majority of operative treatments for core muscle injury are successful.[12,16,19,29,32,46] Debate exists as to the best technique for repair. Large prospective studies comparing open, laparoscopic, and minimally invasive techniques are lacking. Because of heterogeneous populations and small sample sizes, meta-analyses of operative treatment have not been reported.

When investigators compared 1-year outcomes of physical therapy versus surgical repair of chronic (>3 months) groin pain from a sports hernia, the surgical group had a significantly better rate of return to full sports and improvement in symptoms.[41] Specifically, 90% of the athletes who underwent operation returned to sports after 3

months compared with 27% of athletes in the nonoperative group ($P < .0001$). Additionally, 7 of the 30 (23%) patients in the physical therapy group crossed over to the surgical group because of persistent groin pain despite 8 weeks of supervised therapy. These data suggest a role for operative intervention to achieve earlier return to play. The presence of athletic pubalgia in both groups may be a poor prognosticator, although, as one matched cohort study of National Football League (NFL) athletes reported that the control players remained in the NFL for more seasons and played more games than the group with a core muscle injury. Despite the shorter playing career of the affected athletes, surgical management was successful with a 94.7% return-to-play rate and no difference in postsurgical performance.[24]

Multiple laparoscopic mesh repair techniques have been described, which carry the advantage of a faster recovery and return to sports (range, 2-6 weeks)[6,23,41] compared with open procedures (range, 1-6 months).[48] After using a laparoscopic, transabdominal preperitoneal repair technique with mesh, investigators reported a 100% return to sports within 2 to 3 weeks.[18] Furthermore, Le et al[32] reported on 93 patients (mean age 23.4 years) who underwent extraperitoneal laparoscopic repair with concomitant adductor tenotomy. Only 60% of these patients had undergone a preoperative MRI, and of these, 52% demonstrated notable pathology. At follow-up, 92.5% of patients had been able to return to play in 28 days. Most important, the authors reported a low postoperative complication rate, with 7% symptom recurrence, 2% having urinary retention, and 1 instance of delayed hematoma at 3 months postoperatively.[32] A large series of 130 patients treated with endoscopic repair demonstrated a high patient satisfaction rate of 98.5% and no recurrences at 6-year follow-up. One patient in this series experienced a postoperative hematoma, and 4.6% had mild numbness around the surgical site, which resolved by 6 months postoperatively. The mean return to sports in this cohort was at 6 weeks.[28]

With respect to open repair, patients who had undergone the Gilmore (open) repair technique were reported to have a return-to-sports rate of 96% at 15 weeks.[9] A technique of open pelvic floor repair and reattachment of the rectus abdominis resulted in a 95% rate of return to sports at 3 months postoperatively.[35] Without further specifying which particular repair technique was used, a study of professional hockey players who underwent sports hernia surgery reported that 80% of players were able to return to play for 2 or more seasons but with significantly lower performance levels in veteran players.[25]

Across the literature, when open and laparoscopic techniques are compared, the time to return to play is consistently shorter with laparoscopic techniques.[23] One randomized clinical trial comparing open repair versus extraperitoneal repair demonstrated a positive early effect from the laparoscopic technique with lower pain scores at 1 month. This effect was negligible by 3 months, with no difference in return-to-sports rate at this time point.[45] A retrospective comparison of minimally invasive repair versus open Bassini repair showed a quicker return to sports (5.6 vs 25.8 weeks, respectively), with only 64% of open repair athletes returning to their preinjury level of sports.[13] In contrast, 93% of the athletes undergoing the minimally invasive repair technique returned to preinjury level of sports.

Combined FAI and Pubalgia

Clinical overlap between conditions has been observed, and a 2012 cadaveric study demonstrated abnormal stresses at the anterior pubic symphysis in hips with cam deformities.[8] Preexisting FAI may be a predisposing factor to athletic pubalgia by means of altered biomechanics. In patients with coexisting intra-articular hip pathology, both the core muscle injury and the hip must be addressed to achieve optimal results.[14,30,31,44] One study evaluated the timing of surgical intervention in 27 hips with concomitant pathology; the authors noted an overall 89% return-to-play rate with no differences in outcome scores between patients who underwent primary hip arthroscopy, secondary arthroscopy, or simultaneous arthroscopy with core muscle injury repair.[31] Of note, 39% of athletes had resolution of pubalgia symptoms after FAI surgery alone, which has been postulated to correct the muscular imbalances across the symphysis. Many studies suggest that a reasonable approach to an asymptomatic athlete is to address FAI with hip arthroscopy before addressing the pubalgia with operative treatment due to possible resolution of symptoms.[31,44] When high-level professional or collegiate athletes are treated, combining both surgeries in a single setting may allow for the best single approach to ensure an expeditious return to play.[44]

Combined Adductor Tendinopathy and Pubalgia

Return to play after athletic pubalgia repair with the incorporation of an adductor tenotomy is successful but is delayed compared with repair without adductor tenotomy. One study evaluated 30 male professional soccer players at 2-year follow-up status after partial symphyseal resection and adductor tenotomy. The authors demonstrated a 100% satisfaction rate and 100% return to play. Practice was allowed at 8 weeks and game competition at 16 weeks.[12] Another retrospective study examined 85 patients who underwent concomitant pubalgia repair with an adductor longus fractional lengthening and a turn-up flap of the released tendon onto the rectus abdominis for imbricated reinforcement. This combined approach addressed the simultaneous pathologies and had a high subjective success rate; 82 patients (96%) returned to sports at a mean of 4.1 months, and the athletes rated their overall hip function at 98% and sports function at 92% of its preoperative values.[16]

Gill et al[19] reported on a series of elite athletes who underwent adductor longus tenotomy with or without concomitant sports hernia repair. A total of 28 patients were collegiate or professional athletes who underwent adductor longus tenotomy with an average follow-up time of 6.2

years (range, 1.0-14.8 years). Of the 28 patients, 15 had a concomitant sports hernia repair in addition to an adductor longus tenotomy. At follow-up, 27 patients (96.4%) reported a significant improvement in their symptoms, and 20 patients (71.4%) were completely asymptomatic at the time of follow-up. In total, 26 patients (92.8%) were able to return to their previous level of play, and the same number reported that they would undergo surgery again. No players reported weakness or subjective decrease in running speed or power. Return to sport averaged 12 weeks after surgery. In a subgroup analysis of 16 NFL players, there were no statistically significant differences for the preoperative versus postoperative comparison of the athlete performance scores ($P = .7$) and the percentage of games started versus games played ($P = .13$). Patients with core muscle injury repair did not have a significant difference in performance scores ($P = .66$). There was a tendency toward a greater number of games started postoperatively in patients with isolated adductor longus tenotomy compared with those who had concomitant core muscle injury repair ($P = .05$).

CONCLUSION

The differential diagnosis of groin pain in an athlete should include core muscle injury, with or without adductor longus tendinopathy. Pain localized above the inguinal ligament, especially in conjunction with tenderness at the insertion of the rectus abdominis to the pubis, is highly suggestive of a sports hernia. Imaging modalities such as plain radiographs, dynamic ultrasonography, and MRI are useful to rule out other pathologies such as FAI, stress fractures, and inguinal hernias. However, the diagnosis of a sports hernia is clinical in nature and cannot be made using imaging alone. A nonoperative rehabilitation program consisting of a minimum of 2 months of formal therapy is often successful. These programs begin with flexibility, then move on to trunk and lower extremity strengthening, progress to core stability, and finally address sport-specific function in order to return an athlete to pain-free sports activities. If an athlete has persistent symptoms despite 12 weeks of nonoperative treatment, surgical repair using mesh and a relaxing myotomy of the conjoined tendon should be considered. Concomitant adductor longus pathology is not uncommon in athletes and can be diagnosed with tenderness over the adductor longus pubic attachment as well as pain with resisted hip adduction. Return to play after surgery for an isolated sports hernia is typically 4 weeks. If a concomitant adductor release is performed, return to play is typically 12 weeks postoperatively. Return to sport can be expected with a high level of postoperative function.

ORCID iD

Julianne M. Forlizzi https://orcid.org/0000-0003-0727-0436

REFERENCES

1. Abouelnaga WA, Aboelnour NH. Effectiveness of active rehabilitation program on sports hernia: randomized control trial. *Ann Rehabil Med*. 2019;43(3):305-313.
2. Ahumada LA, Ashruf S, Espinosa-de-los-Monteros A, et al. Athletic pubalgia: definition and surgical treatment. *Ann Plast Surg*. 2005; 55(4):393-396.
3. Akermark C, Johansson C. Tenotomy of the adductor longus tendon in the treatment of chronic groin pain in athletes. *Am J Sports Med*. 1992;20(6):640-643.
4. Akita K, Niga S, Yamato Y, Muneta T, Sato T. Anatomic basis of chronic groin pain with special reference to sports hernia. *Surg Radiol Anat*. 1999;21(1):1-5.
5. Albers SL, Spritzer CE, Garrett WE Jr, Meyers WC. MR findings in athletes with pubalgia. *Skeletal Radiol*. 2001;30(5):270-277.
6. Azurin DJ, Go LS, Schuricht A, McShane J, Bartolozzi A. Endoscopic preperitoneal herniorrhaphy in professional athletes with groin pain. *J Laparoendosc Adv Surg Tech A*. 1997;7(1):7-12.
7. Becker LC, Kohlrieser DA. Conservative management of sports hernia in a professional golfer: a case report. *Int J Sports Phys Ther*. 2014;9(6):851-860.
8. Birmingham PM, Kelly BT, Jacobs R, McGrady L, Wang M. The effect of dynamic femoroacetabular impingement on pubic symphysis motion: a cadaveric study. *Am J Sports Med*. 2012;40(5):1113-1118.
9. Brannigan AE, Kerin MJ, McEntee GP. Gilmore's groin repair in athletes. *J Orthop Sports Phys Ther*. 2000;30(6):329-332.
10. Cavalli M, Bombini G, Campanelli G. Pubic inguinal pain syndrome: the so-called sports hernia. *Surg Technol Int*. 2014;24:189-194.
11. Davies AG, Clarke AW, Gilmore J, Wotherspoon M, Connell DA. Review: imaging of groin pain in the athlete. *Skeletal Radiol*. 2010;39(7):629-644.
12. de Queiroz RD, de Carvalho RT, de Queiroz Szeles PR, Janovsky C, Cohen M. Return to sport after surgical treatment for pubalgia among professional soccer players. *Rev Bras Ortop*. 2014;49(3):233-239.
13. Economopoulos KJ, Milewski MD, Hanks JB, Hart JM, Diduch DR. Sports hernia treatment: modified Bassini versus minimal repair. *Sports Health*. 2013;5(5):463-469.
14. Elattar O, Choi HR, Dills VD, Busconi B. Groin injuries (athletic pubalgia) and return to play. *Sports Health*. 2016;8(4):313-323.
15. Ellsworth AA, Zoland MP, Tyler TF. Athletic pubalgia and associated rehabilitation. *Int J Sports Phys Ther*. 2014;9(6):774-784.
16. Emblom BA, Mathis T, Aune K. Athletic pubalgia secondary to rectus abdominis-adductor longus aponeurotic plate injury: diagnosis, management, and operative treatment of 100 competitive athletes. *Orthop J Sports Med*. 2018;6(9):2325967118798333.
17. Farber AJ, Wilckens JH. Sports hernia: diagnosis and therapeutic approach. *J Am Acad Orthop Surg*. 2007;15(8):507-514.
18. Genitsaris M, Goulimaris I, Sikas N. Laparoscopic repair of groin pain in athletes. *Am J Sports Med*. 2004;32(5):1238-1242.
19. Gill TJ, Wall AJ, Gwathmey FW, et al. Surgical release of the adductor longus with or without sports hernia repair is a useful treatment for recalcitrant groin strains in the elite athlete. *Orthop J Sports Med*. 2020;8(1):2325967119896104.
20. Gilmore J. Groin pain in the soccer athlete: fact, fiction, and treatment. *Clin Sports Med*. 1998;17(4):787-793, vii.
21. Hackney RG. The sports hernia: a cause of chronic groin pain. *Br J Sports Med*. 1993;27(1):58-62.
22. Hopkins JN, Brown W, Lee CA. Sports hernia: definition, evaluation, and treatment. *JBJS Rev*. 2017;5(9):e6.
23. Ingoldby CJ. Laparoscopic and conventional repair of groin disruption in sportsmen. *Br J Surg*. 1997;84(2):213-215.
24. Jack RA, Evans DC, Echo A, et al. Performance and return to sport after sports hernia surgery in NFL players. *Orthop J Sports Med*. 2017;5(4):2325967117699590.

25. Jakoi A, O'Neill C, Damsgaard C, Fehring K, Tom J. Sports hernia in National Hockey League players: does surgery affect performance? *Am J Sports Med*. 2013;41(1):107-110.
26. Joesting DR. Diagnosis and treatment of sportsman's hernia. *Curr Sports Med Rep*. 2002;1(2):121-124.
27. Kluin J, den Hoed PT, van Linschoten R, Ijzerman JCJ, van Steensel CJ. Endoscopic evaluation and treatment of groin pain in the athlete. *Am J Sports Med*. 2004;32(4):944-949.
28. Koutserimpas C, Vlasis K, Makris MC, et al. Operative treatment of athletic pubalgia in competitive athletes: a retrospective study. *J Sports Med Phys Fitness*. 2020;60(5):758-763.
29. Kumar A, Doran J, Batt ME, Nguyen-Van-Tam JS, Beckingham IJ. Results of inguinal canal repair in athletes with sports hernia. *J R Coll Surg Edinb*. 2002;47(3):561-565.
30. Larson CM. Sports hernia/athletic pubalgia: evaluation and management. *Sports Health*. 2014;6(2):139-144.
31. Larson CM, Pierce BR, Giveans MR. Treatment of athletes with symptomatic intra-articular hip pathology and athletic pubalgia/sports hernia: a case series. *Arthroscopy*. 2011;27(6):768-775.
32. Le CB, Zadeh J, Ben-David K. Total extraperitoneal laparoscopic inguinal hernia repair with adductor tenotomy: a 10-year experience in the treatment of athletic pubalgia. *Surg Endosc*. 2021;35(6):2743-2749.
33. Litwin DE, Sneider EB, McEnaney PM, Busconi BD. Athletic pubalgia (sports hernia). *Clin Sports Med*. 2011;30(2):417-434.
34. Meyers WC, Foley DP, Garrett WE, Lohnes JH, Mandelbaum BR. Management of severe lower abdominal or inguinal pain in high-performance athletes. PAIN (Performing Athletes with Abdominal or Inguinal Neuromuscular Pain Study Group). *Am J Sports Med*. 2000;28(1):2-8.
35. Meyers WC, McKechnie A, Philippon MJ, Horner MA, Zoga AC, Devon ON. Experience with ''sports hernia'' spanning two decades. *Ann Surg*. 2008;248(4):656-665.
36. Mullens FE, Zoga AC, Morrison WB, Meyers WC. Review of MRI technique and imaging findings in athletic pubalgia and the ''sports hernia.'' *Eur J Radiol*. 2012;81(12):3780-3792.
37. Muschaweck U, Berger L. Minimal repair technique of sportsmen's groin: an innovative open-suture repair to treat chronic inguinal pain. *Hernia*. 2010;14(1):27-33.
38. Muschaweck U, Berger LM. Sportsmen's groin—diagnostic approach and treatment with the minimal repair technique: a single-center uncontrolled clinical review. *Sports Health*. 2010;2(3):216-221.
39. Naal FD, Dalla Riva F, Wuerz TH, Dubs B, Leunig M. Sonographic prevalence of groin hernias and adductor tendinopathy in patients with femoroacetabular impingement. *Am J Sports Med*. 2015;43(9):2146-2151.
40. Nejati P, Sartaj E, Imani F, Moeineddin R, Nejati L, Safavi M. Accuracy of the diagnostic tests of sacroiliac joint dysfunction. *J Chiropr Med*. 2020;19(1):28-37.
41. Paajanen H, Brinck T, Hermunen H, Airo I. Laparoscopic surgery for chronic groin pain in athletes is more effective than nonoperative treatment: a randomized clinical trial with magnetic resonance imaging of 60 patients with sportsman's hernia (athletic pubalgia). *Surgery*. 2011;150(1):99-107.
42. Rab M, Ebmer, Dellon AL. Anatomic variability of the ilioinguinal and genitofemoral nerve: implications for the treatment of groin pain. *Plast Reconstr Surg*. 2001;108(6):1618-1623.
43. Reiman MP, Goode AP, Hegedus EJ, Cook CE, Wright AA. Diagnostic accuracy of clinical tests of the hip: a systematic review with meta-analysis. *Br J Sports Med*. 2013;47(14):893-902.
44. Ross JR, Stone RM, Larson CM. Core muscle injury/sports hernia/athletic pubalgia, and femoroacetabular impingement. *Sports Med Arthrosc Rev*. 2015;23(4):213-220.
45. Sheen AJ, Montgomery A, Simon T, Ilves I, Paajanen H. Randomized clinical trial of open suture repair versus totally extraperitoneal repair for treatment of sportsman's hernia. *Br J Surg*. 2019;106(7):837-844.
46. Sheen AJ, Stephenson BM, Lloyd DM, et al. Treatment of the sportsman's groin: British Hernia Society's 2014 position statement based on the Manchester Consensus Conference. *Br J Sports Med*. 2014;48(14):1079-1087.
47. Steele P, Annear P, Grove JR. Surgery for posterior inguinal wall deficiency in athletes. *J Sci Med Sport*. 2004;7(4):415-421.
48. Swan KG Jr, Wolcott M. The athletic hernia: a systematic review. *Clin Orthop Relat Res*. 2007;455:78-87.
49. Taylor DC, Meyers WC, Moylan JA, Lohnes J, Bassett FH, Garrett WE Jr. Abdominal musculature abnormalities as a cause of groin pain in athletes: inguinal hernias and pubalgia. *Am J Sports Med*. 1991;19(3):239-242.
50. Vasileff WK, Nekhline M, Kolowich PA, Talpos GB, Eyler WR, van Holsbeeck M. Inguinal hernia in athletes: role of dynamic ultrasound. *Sports Health*. 2017;9(5):414-421.
51. Weir A, Brukner P, Delahunt E, et al. Doha agreement meeting on terminology and definitions in groin pain in athletes. *Br J Sports Med*. 2015;49(12):768-774.
52. Woodward JS, Parker A, Macdonald RM. Non-surgical treatment of a professional hockey player with the signs and symptoms of sports hernia: a case report. *Int J Sports Phys Ther*. 2012;7(1):85-100.
53. Zajick DC, Zoga AC, Omar IM, Meyers WC. Spectrum of MRI findings in clinical athletic pubalgia. *Semin Musculoskelet Radiol*. 2008;12(1):3-12.
54. Zuckerbraun BS, Cyr AR, Mauro CS. Groin pain syndrome known as sports hernia: a review. *JAMA Surg*. 2020;155(4):340-348.